


Oral Assessment, Treatment and Prevention

Jan Bellows, DVM, DAVDC, DABVP



Oral disease is one of the most common, yet serious health problems in veterinary medicine—affecting approximately 80% of dogs and 70% of cats by age three.¹ The Oral Assessment, Treatment and Prevention, or ORAL ATP™, protocol helps veterinarians minimize this risk, improve client compliance and develop sound oral healthcare practices.

A number of excellent resources exist to assist the general practitioner in developing a sound oral healthcare practice by implementing ORAL ATP™. On-demand CE credit webinars, technical reports, staff guides and client communication pieces are available at vet.greenies.com. In addition, a new online resource—**OralATP.com**—provides the most convenient, comprehensive and in-depth source of information on every aspect of oral assessment, treatment and prevention.

Table of Contents

Assessment	1–3
Patient History	1
The General Physical and Laboratory Exam	2
The Facial Exam	2
Anesthesia	3
Oral Examination Under Anesthesia	3
Intraoral Radiology	3
The Dental Chart	3
Treatment	4–7
Dental Equipment	4
Congenital Disease	4
Periodontal Disease	5
Fractured Teeth	5
Orthodontics	6
Feline Stomatitis	6
Tooth Resorption	6
Oral Tumors	7
Prevention	7–9
Tooth Brushing	7
Dental Diets	8
Adjunctive Plaque Control Therapies	8
Dental Treats	9
Follow-Up Dental Visits	9

Assessment

The oral assessment begins in the exam room and continues with a systematic tooth-by-tooth examination under anesthesia to ensure no oral problems go untreated.

A comprehensive oral assessment is the cornerstone to:

- Communicating the importance of regular oral care to your clients
- Improving your clinic’s level of wellness care
- Reducing the prevalence of periodontal disease among your patients

Patient History

Before the physical examination, at least 10 key questions need to be answered prior to performing an oral exam.

- Is the animal showing abnormal signs that might indicate oral disease such as difficulty chewing, inability to open or close the mouth and/or excessive salivation?
- Does the patient’s breath smell bad? Halitosis, the offensive odor that accompanies periodontal disease, results from the bacteria associated with plaque, calculus, diseased gingiva and decomposing food particles retained in periodontal pockets.
- What are your client’s goals for his/her pet’s oral health? If your client wants to establish and maintain a healthy mouth for the pet, the oral assessment provides the necessary information to make appropriate treatment and prevention recommendations.
- What is your client doing now at home for the pet’s oral health? The gold standard is tooth brushing daily to control plaque.
- Would your client be willing and able to brush or wipe the pet’s teeth twice daily? Plaque, the precursor of periodontal disease, accumulates within 12 hours of thorough teeth cleaning. Unless it is removed daily, plaque remains on the tooth surface and often irritates the gingiva. Also, salivary minerals change the plaque to calculus and that attracts more plaque, eventually leading to periodontal disease (*Fig. 1*).
- Will your patient allow brushing or wiping of the teeth once or twice daily? If a dog or cat will not allow manual plaque control, Veterinary Oral Health Council (VOHC) approved dental diets and treats are the best alternatives to help control plaque and calculus.
- What does your patient eat? Soft and semi-soft foods accumulate below the canine and feline gingival lines and promote periodontal disease. Hard kibble food crumbles easily when chewed, contributing to plaque accumulation. Dental diets remain intact longer and have been shown to help reduce the buildup of plaque.
- What kind of chew toys does your patient have? Inappropriate toys can break teeth and hurt an animal’s gingiva. Generally, all chew toys need to be able to bend. Recommend avoiding cow or horse hooves, nylon products, bones, ice cubes or any toy that is harder than the pet’s teeth. Hard rubber and soft, bendable chew toys are considered safer for teeth. Encourage clients to monitor pets at all times when chewing on a toy so that pets do not ingest inedible items.

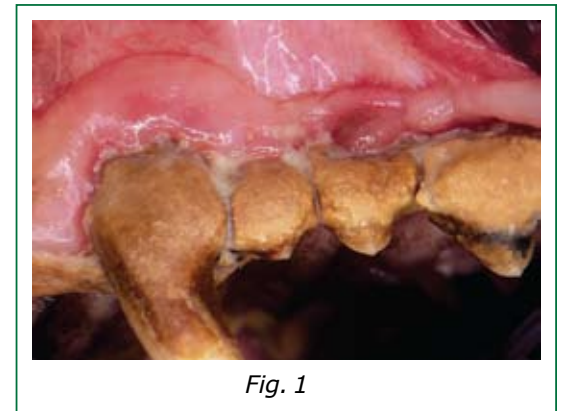


Fig. 1

- Does your patient currently receive dental treats? If so, how often? Several dental treats have been thoroughly researched for plaque and calculus control by the Veterinary Oral Health Council (VOHC) and awarded the VOHC Seal of Acceptance. A list of these may be found on www.VOHC.org.
- When was the last time the patient had a professional teeth cleaning? What, if any, dental care has the pet received in the past? ORAL ATP™ visits should be scheduled semi-annually or annually for most cats and dogs on a daily plaque control program. Other pets need more frequent examinations and dental care to prevent periodontal inflammation.

After reviewing these questions with your client, move to the physical examination.

The General Physical and Laboratory Exam

Always conduct a general physical health exam before anesthetizing your patient. Inspect the eyes, ears, nose, throat and auscultation of the heart and lungs and feel the abdomen for areas of discomfort or swelling. Then determine which preoperative tests should be performed before anesthesia. Consider variables such as other diseases your patient may have, age and the estimated length of procedure.

All patients should have pre-anesthetic blood tests. Generally older patients and patients with other diseases (i.e., kidney, liver, diabetes) will require more tests before anesthesia and surgery. Some common tests include:

- Cell blood count (CBC)
- Serum chemistry profile
- Coagulation tests
- Electrocardiogram (ECG)/Blood pressure
- X-rays of the chest and abdomen

The Facial Exam

Most oral conditions, such as broken teeth and periodontal disease, can be briefly evaluated on an awake patient. The extent of an examination on an awake cat or dog depends on patient cooperation. Unfortunately, some patients with oral disease may be in too much pain for examination without sedation or general anesthesia. Further assessment (x-rays, probing, biopsy) is required under general anesthesia to tailor specific therapies.

On conscious patients, while looking into the patient's eyes, feel along the upper and lower jaws for signs of malformation, discharge, discomfort or swelling (Fig. 2). Check for enlarged lower jaw lymph nodes indicative of infection, inflammation or neoplasia. Examine the animal's lips to make sure they're not swollen or inflamed.

When inspecting the mouth, hold the head steady in one hand and pull the lips backward to examine how the teeth meet. Check for abnormalities in the teeth, disease or oral masses.

Open and close the mouth several times to evaluate the temporomandibular joints. Evaluate the bite, the hard palate, the floor of the mouth, the top and underside of the tongue and the gingiva.



Fig. 2

Anesthesia

General anesthesia is required to properly diagnose and treat dental disease in companion animals. Patient safety is everyone's top concern. An important part of the anesthesia safety trilogy—choosing the correct patient, anesthesia protocol and patient monitoring—is preoperative patient testing after the physical examination.

Pet owners often express concern about anesthesia. Some clients may have more than one concern, especially in the case of two pet owners for the same pet. Be sure to always speak to each person about his/her particular concerns.

Oral Examination Under Anesthesia

The foundation of an oral assessment is a visual tooth-by-tooth examination under anesthesia, with the help of a periodontal probe, an explorer and dental X-rays.

Every ORAL ATP™ visit conducted under general anesthesia should include probing and charting. Depending on their sizes, dogs without periodontal disease have probing depths less than 1–4 mm. Cats normally have probing depths less than 1 mm. Greater depths may indicate periodontal disease requiring treatment.

At the end of the visual and probing examination, complete a dental chart to identify observed pathology and to develop a treatment plan that will address any abnormalities.

Intraoral Radiology

Intraoral radiography offers the capability to view pathology below the gingival line as well as inside and around the tooth. Use dental films as part of a complete yearly oral assessment to evaluate apparent pathologies and monitor progression or resolution of treated disease. The radiography step is an integral part of ORAL ATP™ and should not be skipped unless necessary. Films have revealed disease not visible to the eye in more than 75% of cases² (Fig. 3).

OralATP.com provides excellent information on types and uses of radiography equipment.

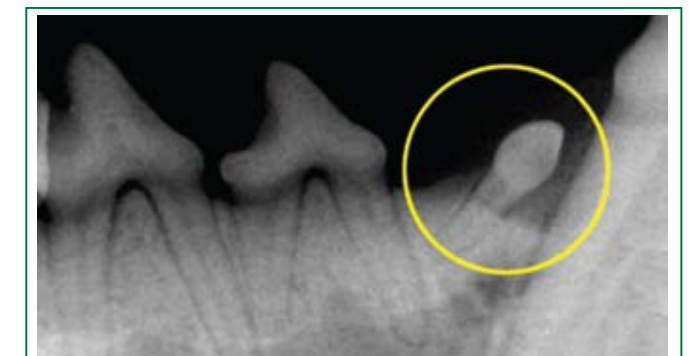

Fig. 3

The Dental Chart

Recording the condition of all teeth as well as soft and hard tissues during the ORAL ATP™ visit is necessary to provide quality care. The charting of existing conditions provides basic information for an accurate, comprehensive treatment plan.

The dental chart should include:

- Dental history: Has the patient had professional oral treatment in the past? What is the patient's diet? What is the client doing for home dental care?
- Occlusion abnormalities
- The amount of plaque and calculus present
- Tooth abnormalities
- Periodontal abnormalities: Inflammation, gingival edema, periodontal pocket depths, attachment loss, gingival recession or hyperplasia, furcation involvement or mobility
- Proposed/declined treatment
- Actual treatment

Both a general head examination and an oral exam under anesthesia are essential for thorough charting. Generally, the mouth is charted before cleaning and can be re-charted if a significant amount of calculus has been removed.

Treatment

Upon completion of a thorough oral assessment, it is essential to chart and explain any problems to clients and emphasize the need for treatment. If possible, conduct treatment the same day while the patient is anesthetized. Be sure to clean, polish and probe all teeth one by one, address any abnormalities and discuss an at-home and follow-up care plan.

Dental Equipment

You will need specialized equipment to diagnose and treat canine and feline dental problems. When proper equipment or training is not available, a referral to a dental specialist is recommended.

Common pieces of dental equipment include:

- Dental table, chair and lighting
- Hand instruments
- Polishing tools
- Intraoral radiography equipment
- Anesthesia delivery equipment
- Patient monitoring tools

Please see **OralATP.com** for a complete list.

Specific Diseases

Performing oral treatment for pathology found during the tooth-by-tooth examination requires broad knowledge of the different types of oral diseases and conditions. The following sections review oral health problems that you may encounter with your patients as well as recommended therapies.

Congenital Disease

Congenital diseases are present at birth. They can be a result of inherited abnormalities, gestation environment or a mixture of both. A congenital disorder can have minor or major consequences. Be sure to check a puppy or kitten for congenital disease as part of the initial examination.

Retained deciduous teeth—An adult tooth erupts next to a deciduous tooth, dislodging it into an abnormal location (*Fig. 4*). Remove the deciduous tooth so the adult tooth can have sufficient room to erupt properly.

Missing teeth—Either the patient was born without a tooth or it is impacted below the gum line. If an impacted tooth is oriented normally, perform an operculectomy (for patients younger than nine months) or extract the tooth. If the tooth is abnormally oriented, it must be extracted.

Extra (supernumerary) teeth—Extra teeth erupt in places they do not belong. If an extra tooth creates crowding, extract the tooth. If not, leave it in place and periodically follow up to make sure no inflammation occurs.

Rotated teeth—A result of retained deciduous teeth, trauma or an inherited defect. If a rotated tooth affects adjacent teeth or gingiva, it should be extracted.

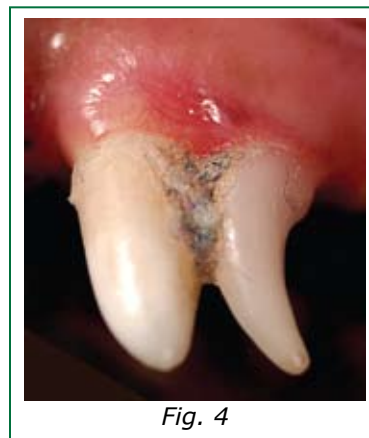

Fig. 4

Periodontal Disease

Periodontal disease is one of the most common, yet serious issues in veterinary medicine. It directly affects the tooth support and may indirectly affect vital organs, including the heart, kidneys and brain. The disease starts as a minor reaction to plaque (gingivitis) and often progresses to major inflammation, pain and tooth loss.

Stage 1: Gingivitis

Therapy involves removing plaque and calculus from the teeth and encouraging pet owners to perform home care such as tooth brushing, using wipes and/or giving dental treats.

Stage 2: Early periodontal disease (<25% tooth support is lost)

Therapy involves removing a small amount of gum tissue (gingivectomy) or applying a local antibiotic such as Doxirobe (Pfizer) in cases of small pockets. Where there is gum recession, usually home preventive care is all that is recommended after the teeth are cleaned.

Stage 3: Established periodontal disease (25%–50% tooth support is lost)

Therapy involves decreasing or eliminating the periodontal pocket if present.

Stage 4: Advanced periodontal disease (>50% tooth support is lost)

Because there is very little support of the teeth, extraction is the treatment of choice. Prevention of periodontal disease affecting adjacent teeth is very important.

Common warning signs of periodontal disease include:

- Plaque and calculus buildup
- Gingival recession
- Mobile teeth
- Excessive salivation
- Chewing difficulties
- Halitosis

It is critical that we effectively communicate the risks of periodontal disease to our clients and gain their compliance for optimum oral healthcare.

Fractured Teeth

Evaluation is always important to determine the appropriate treatment when canine or feline patients fracture teeth. Even an animal that may not appear to be in pain and is eating normally requires therapy.

Types of fractures:

- Complicated fracture—The pulp (nerve and blood vessels) is exposed to the oral environment.
- Uncomplicated fracture—The pulp is not exposed (*Fig. 5*).

When the pulp of a tooth is exposed to the oral environment, the tooth must be treated either by root canal or extraction. Base your decision on the tooth's general condition, equipment and materials available and the availability for a referral.

A discolored tooth (pulpitis) occurs from trauma. In most cases, the pulp is dead and should be removed via root canal or the tooth may need to be extracted.

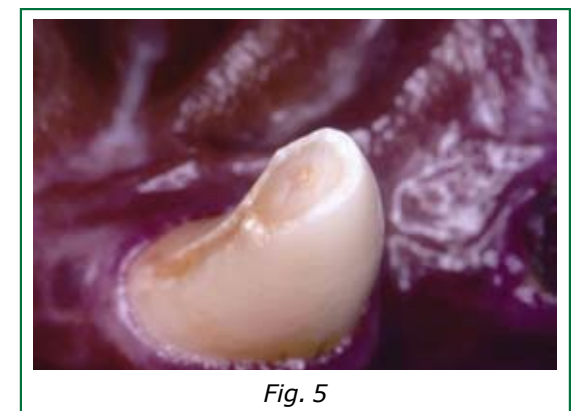


Fig. 5

Orthodontics

Canine and feline orthodontic problems occur from either inherited jaw length discrepancies called skeletal malocclusion, or from individual teeth that have erupted in abnormal locations and caused injury, called dental malocclusion. Orthodontic issues include:

- Base narrow (lingually displaced) canines—The lower canines are deflected toward the midline and penetrate the hard palate.
- Rotated teeth—Occur from retained deciduous teeth, a trauma or an inherited defect.
- Rostral crossbite—One or more of the upper incisor teeth are located behind the lower jaw counterpart in a dog that has a mesaticephalic skull type.
- Mandibular mesiocclusion (underbite)—A skeletal abnormality in which the lower jaw is abnormally in front of the upper jaw.
- Mandibular distocclusion (overbite)—A skeletal abnormality in which the lower jaw is abnormally behind the upper jaw.
- Lance canine (rostrally deviated canine)—Either the upper or lower canines are abnormally pointed forward.

In these cases, orthodontic care is recommended to move or remove teeth in order to create a pain-free mouth. Sometimes teeth are moved with elastic bands attached to cemented brackets on the teeth. Other times fixed appliances are installed on one jaw to move the teeth on the opposite jaw into a functional bite. When teeth cannot be moved to correct positions, they can be reduced in height and restored or they might need to be extracted.

Feline Stomatitis

Stomatitis occurs as a generalized inflammation around the teeth and often affects the back of the mouth. Many therapy options exist, but extraction of the teeth behind the canines has traditionally resulted in the most consistent success.

Extraction results in cases of feline chronic gingivostomatitis:

- 60% are cured
- 20% require further therapy (medication, laser)
- 20% experience little improvement

Tooth Resorption

Canine and feline teeth may be affected by decreased tooth substance called tooth resorption. External resorption starts from the outside of the tooth and progresses inward. Internal resorption begins at the pulp (nerve) and progresses outward. The exact cause of tooth resorption is unknown (*Fig. 6*).

Recommended therapy for canine patients:

- For internally resorbed teeth—Extract the tooth or perform a root canal.
- Externally resorbed teeth—if the resorption extends to the oral cavity, extract the tooth. If not, monitor the patient closely with periodic clinical and radiographic examinations.

Therapy for feline patients depends on the visualization of the periodontal ligament.

If the periodontal ligament is present, the tooth should be extracted. X-rays should be taken afterward to ensure complete extraction.

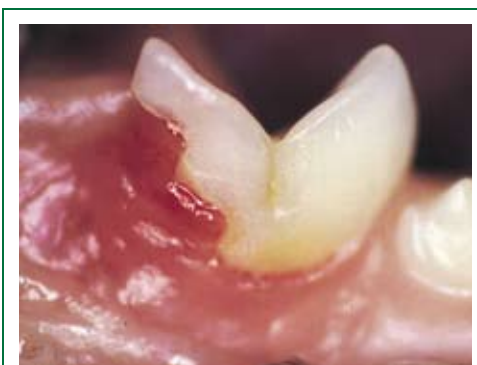

Fig. 6

If the periodontal ligament is absent, the exposed crown should be surgically removed, leaving the root. The surrounding gum tissue should be sutured over the defect, allowing the root to continue to resorb.

Oral Tumors

Oral tumors can occur in both dogs and cats. As soon as you observe a tumor, perform diagnostic tests, including cell examination (cytology and/or histopathology) to determine whether the tumor is malignant or benign.

Benign oral tumors can often be surgically removed, resulting in a cure. Malignant oral tumors usually carry a guarded to poor prognosis in dogs and cats.

Melanoma is the most common type of oral tumor in canine patients. Squamous cell carcinoma is the most common oral tumor in cats and the second most common type in dogs.

Treatment depends on many variables, including size, location and classification as benign or malignant. The goal when performing tumor removal should be to include a wide surgical margin around the lesion—1 cm for benign lesions and 2 cm for malignant lesions.

Prevention

The hospital staff plays a crucial role in the prevention of companion animal oral disease through client education, demonstration of plaque control techniques starting with puppies and kittens, providing safe and effective plaque control products for clients to feed or treat their pets at home and scheduling follow-up visits to monitor progress. For more information on interaction between hospital staff and clients, please see the section entitled "The ORAL ATP™ Visit" on **OralATP.com**.

Prevention at home is as important as oral assessment and treatment in the clinic. Unless the pet owner is able and willing, and the patient accepts home care, periodontal disease will continue to progress regardless of the care provided by the veterinarian. Daily brushing with a bristled toothbrush is the most effective home care regimen, yet it is rarely practiced. Fortunately, there are other methods of plaque control.

Tooth Brushing

The gold standard of plaque control for canine and feline patients is daily tooth brushing. Devices such as gauze pads, sponge swabs or cotton swabs remove plaque below the gingival line, but cannot adequately clean the space above the gingival line, where plaque and calculus accumulate, as well as tooth brushing.

Convincing clients to brush their pets' teeth regularly is not an easy task. Struggling, biting and/or scratching from an uncooperative pet can quickly cause owners to become reluctant.

To help improve at-home plaque prevention habits, encourage pet owners to begin when the pet is young and to start with a healthy, comfortable mouth. Untreated, painful oral disease will create a non-compliant client.

Choose a proper toothbrush and toothpaste. Toothbrushes should have bristles that reach under the gingival line to clean the space surrounding each tooth. Explain to pet owners that the size of the toothbrush is important. Each dog or cat must have his or her own toothbrush. There are specially made brushes that fit the large mouths of long-muzzled dogs, as well as small brushes for cats.

Do not recommend human toothpastes which contain detergents because dogs and cats will swallow the paste. Pets seem to prefer poultry-flavored pastes.

The toothbrush and toothpaste should be gently introduced under the lip. Pet owners should concentrate on the outside surfaces of the upper teeth. A circular brush motion is the goal, but back and forth will also remove plaque. If an owner senses that a pet is anxious during the brushing procedure, he or she should reassure the pet by talking and trying again. Encourage owners to reward progress immediately with a treat or a play period after each cleaning session.

Toothbrush bristles should be placed at a 45-degree angle at the margin where the teeth and gingiva meet. Pet owners should use an oval pattern, gently forcing the bristle ends into the area around the base of the tooth as well as into the space between the teeth. Ten short back-and-forth motions—covering three to four teeth at a time—should be completed before moving the brush to a new location. The outside of the upper teeth is the area requiring most attention.

Dental Wipes

Cloth pads impregnated with either chlorhexidine or sodium hexametaphosphate can help to control plaque and calculus when rubbed daily against the tooth/gingival interface.

Dental Diets

A patient's diet is important not only from a nutritional standpoint, but also for oral health. Foods can contribute to or control plaque and calculus accumulation.

The myth persists that dry kibble diets are better for the teeth than "wet" diets. Pets that are fed commercial dry diets can still have heavy plaque and calculus accumulation and be at risk for periodontal disease. Most dry pet foods crumble without much resistance, offering little to no abrasive effect from chewing. Dental diets either employ chemicals that specifically join with plaque contents to aid removal or are formulated to scrape plaque away from the tooth surface. Dental diets should be fed as the main calorie source, as recommended.

The Veterinary Oral Health Council (VOHC) recommends foods that have been proven to reduce the accumulation of plaque and/or calculus. A complete list is available at www.vohc.org.

Adjunctive Plaque Control Therapies

Chlorhexidine is indicated in veterinary dentistry in eliminating oral pathogens. It is broad-spectrum and considered efficacious against most oral bacteria, most fungi and some enveloped viruses when in contact with oral surfaces for at least two minutes. The mechanism of action is non-specific, involving disruption of cellular membranes. It binds to oral tissues and teeth and is slowly released at antiseptic levels for up to 12 hours.

Fluoride

Fluoride as a home care product is used in veterinary dentistry to help control plaque, strengthen enamel and desensitize dentin. Only stannous fluoride products have an antibacterial effect derived from the action of the heavy metals on plaque bacteria. Chlorhexidine-based products are more efficacious at eliminating oral pathogens and are safer to use.

Plaque prevention gel

OraVet (Merial) is a plaque barrier gel applied at the time of teeth cleaning and then weekly thereafter to help control plaque by creating a barrier between the tooth and gingival interface.

Dental Treats

Dental treats are products that encourage chewing, exercise the periodontal ligament fibers and cause flushing of oral fluids through the periodontal ligament space. The mechanical abrasion that occurs when canine or feline teeth sink into and scrape against dental treats helps to prevent plaque and calculus buildup. The addition of enzymes and other anti-plaque products may complement this effect.

Treats such as Greenies® canine dental chews and Feline Greenies® dental treats, available through veterinary distributors and commercially, fall into this category.

Many treat products on the market claim efficacy against oral disease. The Veterinary Oral Health Council (VOHC) Seal of Acceptance and proper research can help distinguish products that are scientifically proven to reduce plaque and/or calculus.

VOHC recognizes only those products that meet exacting standards of plaque and/or calculus retardation in dogs and cats. Products are awarded the VOHC Seal of Acceptance following review of data from trials conducted according to VOHC protocols.

A Seal of Acceptance is displayed on products that have been approved. Regular use of products carrying the VOHC Seal of Acceptance has been proven to reduce the accumulation of plaque and/or calculus which can lead to gingivitis, periodontal disease and tooth loss. A complete list is available at www.vohc.org.



Follow-Up Dental Visits

Follow-up dental examinations are essential to monitoring at-home plaque control efforts. During this visit, examine the teeth for areas of calculus and plaque accumulation and assess the efficacy of recommended home-care techniques.

The frequency of follow-up examinations depends on the extent of disease and the willingness of the pet owner to provide—and the patient to accept—home care. More frequent visits should be scheduled for pets that do not receive adequate preventive care at home.



Dr. Jan Bellows is a Fellow of the Academy of Veterinary Dentistry, a Diplomate of the American Board of Veterinary Practitioners, a Diplomate of the American Veterinary Dental College and a Veterinary Information Network (VIN) consultant. He is a frequent speaker at conferences and has authored many articles on veterinary dentistry as well as two books, *The Practice of Veterinary Dentistry: A Team Effort* and *Small Animal Dental Equipment, Materials and Techniques*. Dr. Bellows directed the creation of **OralATP.com**, the veterinary industry's most convenient, comprehensive resource. He practices at All Pets Dental Clinic in Weston, FL.

References

¹American Veterinary Medical Association, 2006.


²Verstraete, FJ, PH Kass, et al. (1998). "Diagnostic value of full-mouth radiography in cats." *Am J Vet Res* 59(6): 692-5.

®/™ Trademarks © S&M NuTec, LLC 2008. All rights reserved.

"I recommend the new Greenies® dental chews for great oral health. They're better tasting and contain antioxidants as well as fiber."



*blah, blah, blah, GREENIES®,
blah, blah, blah, blah, blah.*



More health. Dogs still love them.

Our new, better tasting formula has natural sources of antioxidants and fiber, including apple pomace, sweet potato, tomato and cranberry¹. Recommend Greenies® dental chews, with the VOHC Seal of Acceptance, to protect your patients' oral health. Some may say there's no perfect food, but we think these are the perfect treats.



vet.greenies.com

~ A daily dose of prevention ~

NEW
INGREDIENTS

